2022 年會 台灣乳房腫瘤手術暨重建醫學會
Taiwan Oncoplastic Breast Surgery Society
日期 2022.12.03-04 地點 華南銀行國際會議中心2F (華南銀行總行)

類菱形皮瓣於乳癌病人之應用

林鈺萌[1] 鄭翠芬[1,2]
新光吳火獅紀念醫院外科部 [1]一般外科 [2]乳房外科

Application of Rhomboid flap technique in breast cancer patients

Yu-Meng Claire Lin[1], Fiona Tsui-Feng Cheng[1,2]
[1]Division of General Surgery and [2]Breast Surgery, Department of Surgery, Shin Kong Wu Ho-Su Memorial Hospital, Taipei, Taiwan

Introduction

The rhomboid flap design was first described by the Russian surgeon Alexander Limberg in 1928. Subsequently, rhomboid flap technique has been described in much literature for successful closure of cutaneous defects in numerous anatomical locations and it can be used for a wide range of reconstruction procedures.

Resection of recurrent chest wall tumor in breast cancer patients after mastectomy with implant reconstruction **(Figure 1)** or Paget's disease of the nipple may create a large skin defect **(Figure 4)**. Reconstruction of large skin/chest wall defects is often challenging. Skin graft may be used to cover the defects, but its cosmetic outcome often depends on patient's underlying condition. The rhomboid flap, which can be easily and quickly designed, provides excellent contour, color match and vascularity with a low risk of flap failure.

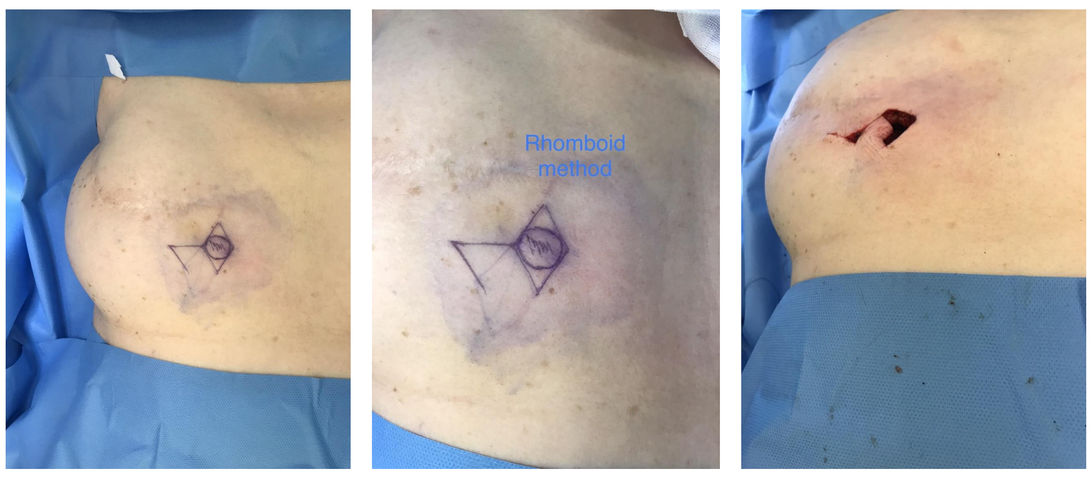

Figure 1: Local recurrence of chest wall tumor in breast cancer patients after previous mastectomy and implant reconstruction

Flap design

The rhomboid flap is a full-thickness local transposition flap that rotates around a pivot point into an adjacent defect **(Figure 2a)**. A rhomboid flap consists of a parallelogram with two angles of 60° and two of 120°. 4 flaps can be produced from one rhomboid **(Figure 2b)**. The rhomboid flaps rely on the dermal-subdermal plexus of blood supply (random blood supply) to provide superiors results when compared to skin grafts of similar size and location. It should be positioned in the direction that produced minimal tension when rotating the flap. In cases of larger sized rhomboid flaps, the blood supply may come from the perforator vessels. The final suture line will be seen as in the **figure 2d**.

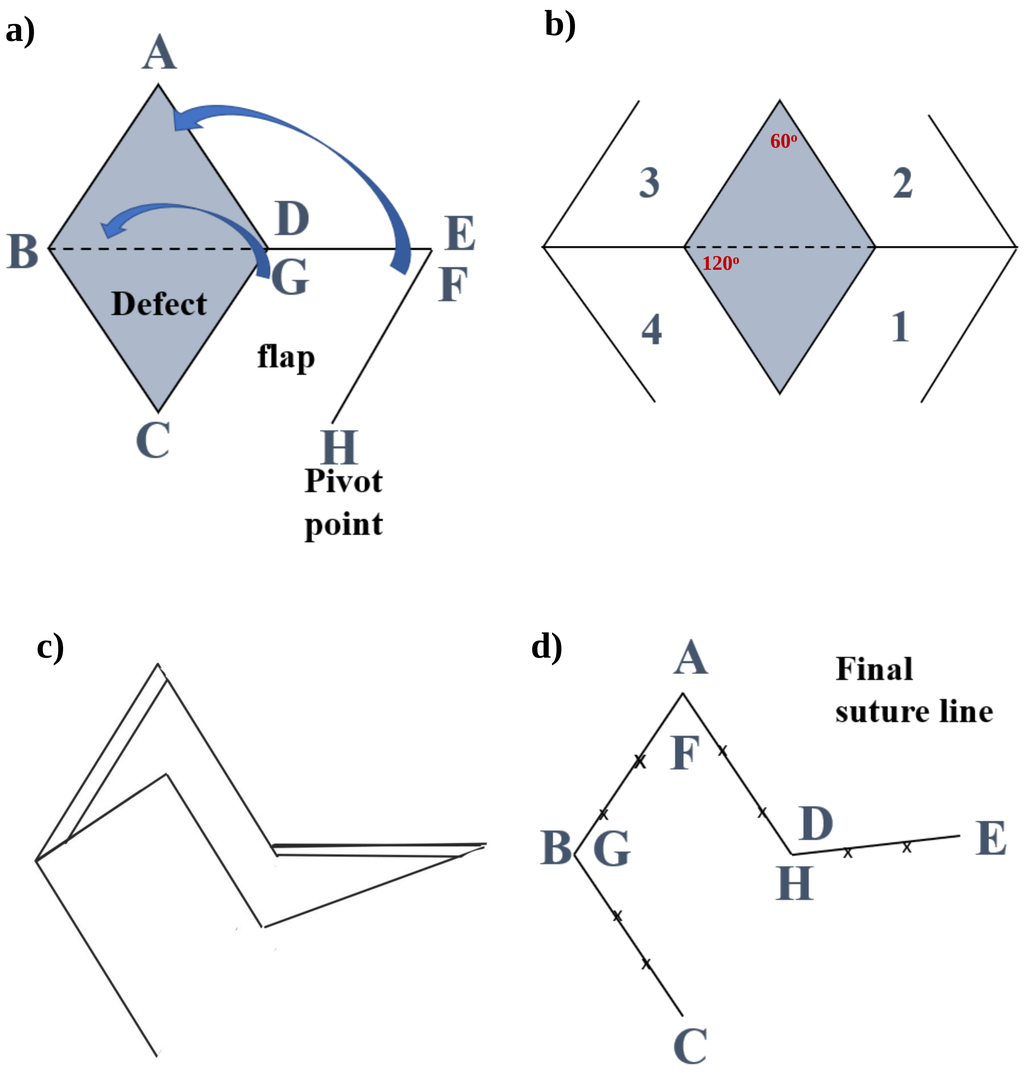

Figure 2: Rhomboid flap design

Discussion

Radiotherapy is commonly used to treat locally advanced breast cancer or breast cancer receiving breast conserving surgery. The common effects include pain, skin changes, and swelling of the breast. Skin damage may cause color changes, peeling or flaking, skin tenderness, and tightness. The following case is a woman who received adjuvant radiotherapy after partial mastectomy and experienced the effect of radiotherapy on the nipple-areolar complex. The skin of the post-radiation breast is very tight and without the normal stretchy texture. Thus, direct resection of the nipple lesion may create a large defect with poor cosmetic effect. We used the rhomboid flap method to repair a such defect. Firstly, we included the lesion in the parallelogram **(Figure 3a)**. Then, 60° and 120° angle rhomboid flaps, at least 2 cm away from the tumor borders, were drawn on the skin surface. An equal-length straight line DE was drawn from the BD line. The FE line which is relatively parallel to AD line was drawn in order to complete the flap border **(Figure 3b).**

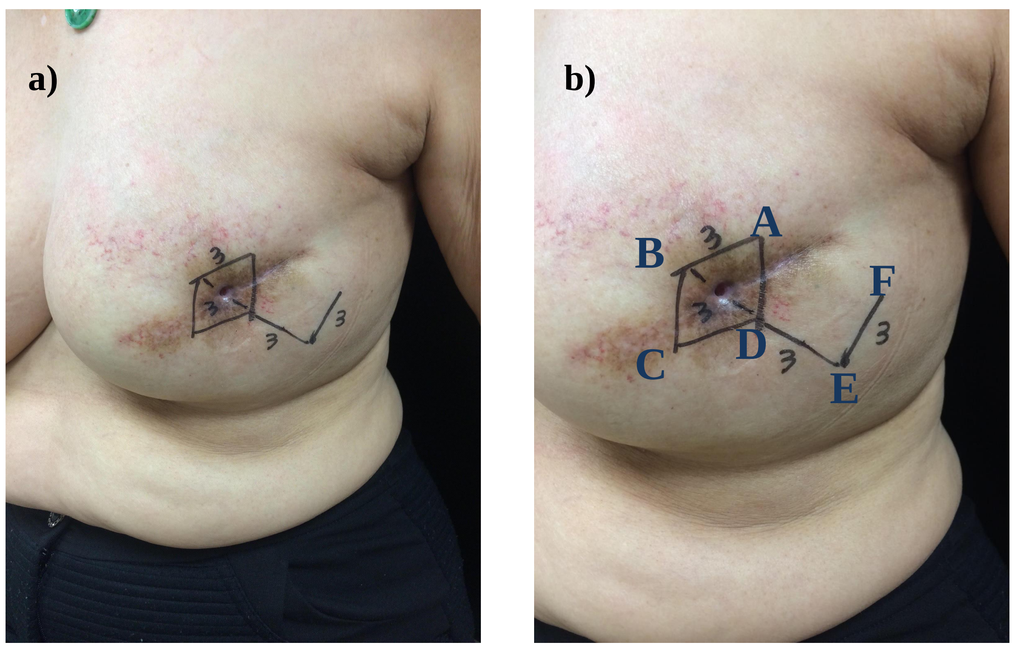

Figure 3: Preoperative marking of the rhombus, defect, and design of the rhomboid flap

Mastectomy and breast conserving surgery (BCS) are commonly performed for breast cancers. However, a "dog ear" often appears at the lateral aspect of the mastectomy scar when using a spindle-shaped incision. The dog ears are often uncomfortable and unsightly. We describe a simple technique, rhomboid flap, for tackling the lateral dog ears. In the case of BCS, the location and design of the flap is dependent on the location of the skin defect. If the skin defect is located within the outer quadrant, both upper and lower, the flap is made laterally to the defect. In the case of a simple mastectomy, a resection line is made and the tumor is resected. Then, two incision lines were made to create a rhomboid flap at the lateral side of the chest. The length of the incision can be modify to create different sizes of the flap in order to fit the size of the skin defect.

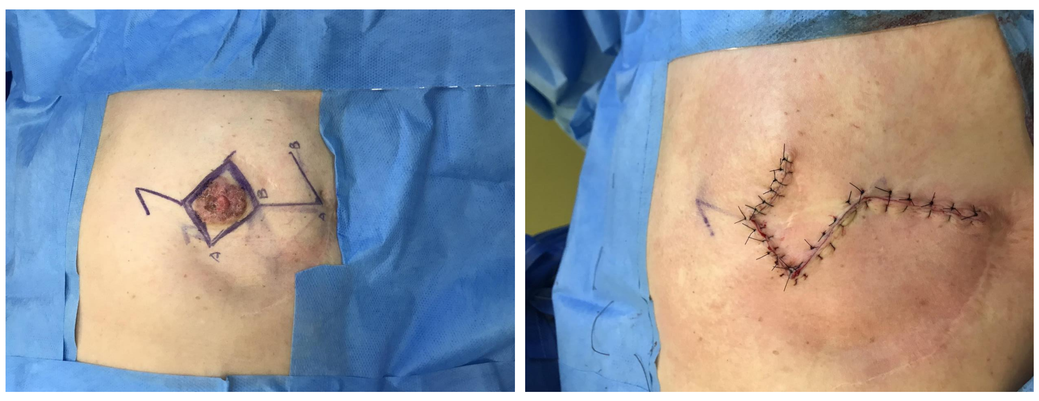

Figure 4: Local recurrence involving the nipple in breast cancer patient after previous mastectomy and implant reconstruction

Conclusions

The rhomboid flap technique has several advantages in addition to being a simple technique to perform. It preserves the breast contour, ensures a smaller donor tract scar, shorter operation time, and matching skin texture and color. It is safe, low cost and more comfortable from patient point of view. In our experience, rhomboid flap is suitable and beneficial for lesions with tight skin, lesions with a larger tumor-to-breast size ratio and it avoids lateral dog ear of the mastectomy scar.